

## Case Report

# A Case of Spontaneous Calf Hematoma Complicating Dengue Hemorrhagic Fever: A Case Report

\*Afsana Begum<sup>1</sup>, Pradip Ranjan Saha<sup>1</sup>, Md Iqbal Hossain<sup>1</sup>, Md Shafiqul Bari<sup>2</sup>

DOI: <https://doi.org/10.3329/bccj.v11i1.66033>

### Abstract:

*Dengue is the most common arboviral infection in the world. Dengue hemorrhagic fever (DHF) presents with manifestations like gum bleeding, melaena, menorrhagia, epistaxis, hemoptysis and sometimes bleeding into the third space all of which are well documented. Spontaneous intra-muscular hematoma is a rare manifestation of DHF; very few such cases have been reported so far. We report a 25-year-old woman who was admitted with DHF and later on developed spontaneous calf muscle hematoma in the soleus muscle.*

**Keywords:** Spontaneous calf hematoma, Dengue hemorrhagic fever.

### Introduction:

Dengue, an arboviral infection has become a major public health concern in Bangladesh. In 2022, a total of 62382 dengue cases were admitted to hospitals, and total death was recorded at 281 which was the highest number in one year period.<sup>1</sup>

Dengue virus causes a wide spectrum of diseases ranging from asymptomatic infection to febrile illness with body aches and hemorrhagic manifestations like petechiae, ecchymosis, epistaxis, gum bleeding, hemoptysis, menorrhagia, hematemeses, melaena and bleeding into body cavities.<sup>2</sup> Spontaneous bleeding into muscle, especially calf muscle is very rare in DHF. To the best of our knowledge, this is the second reported case of spontaneous calf muscle hematoma in DHF from Bangladesh. Here we report a case of muscle hematoma which occurred in the leg along the soleus muscle and its fascial plane during the recovery phase of DHF.

### Case Study:

A 25-year-old woman having dengue NS1 positive was admitted to the special care unit of a private hospital with complaints of high-grade and continued fever for 7days, which was associated with generalized body ache, several episodes of vomiting, three episodes of loose motion and gum bleeding. The patient gave no history of hemoptysis, hematemeses, rashes, confusion, convulsion, or coma.

On admission, the patient was conscious and oriented. His pulse rate was 150/min with a regular rhythm, blood pressure was 100/70 mm of Hg, respiratory rate was 20/min, and SpO<sub>2</sub> was 98% in room air. Systemic examination revealed no

abnormalities. Immediately after admission, her laboratory investigations revealed, hemoglobin: 15.6gm/dl, hematocrit: 47.4%, total white cell count:  $5.5 \times 10^3/\mu\text{l}$ , total platelet count:  $24.4 \times 10^3/\mu\text{l}$ , routine urine examination: normal, alanine aminotransferase: 272U/L, aspartate aminotransferase: 316U/L, serum creatinine: 0.8 mg/dl and random plasma glucose: 4.6 mmol/l. Her chest x-ray was normal, ultrasonogram of the abdomen showed a thick and edematous gall bladder, right-sided minimum perinephric collection with mild ascites, ECG revealed sinus tachycardia and echocardiogram was normal. She was treated with normal saline and paracetamol for DHF as per national guideline and ivabradine for extreme sinus tachycardia. As her fever was continuing and white cell count was raised to  $20.4/\mu\text{l}$ , a blood culture was sent with the suspicion of secondary bacterial infection the report revealed pseudomonas growth and was treated with injection meropenem and the fever responded. Three days after admission, she developed swelling of the left leg which was tender and erythematous (Fig 1). Left calf circumference was 32 cm and right calf circumference was 31 cm. On that day, platelet count was  $33400/\mu\text{l}$ , activated partial thromboplastin time was 48.4, prothrombin time was 14.2 with INR: 1.2, D-dimer was  $3990 \mu\text{g/L}$  (normal range: 0-550  $\mu\text{g/L}$ ) and fibrinogen was 4.25 g/L (normal range: 1.8-3.5 g/L). Ultrasonogram of the left leg also showed hematoma in the medial aspect of the left leg within muscle layer and subcutaneous tissue edema was noted in the medial aspect of the left leg upto the ankle joint (Fig 2) and MRI of the left leg including ankle joint showed bleeding along the left soleus muscle and adjacent fascial plane. Her calf hematoma was treated successfully with limb elevation and active leg exercise. The swelling and pain resolved after two weeks of conservative treatment.

1. Senior Consultant, Internal Medicine, United Hospital Limited, Dhaka.
2. Professor of Medicine, Dhaka Medical College, Dhaka.

### \*Corresponding Author:

Dr. Afsana Begum  
Senior Consultant, Internal Medicine  
United Hospital Limited, Dhaka.  
Email: [afsana.begum@uhlbd.com](mailto:afsana.begum@uhlbd.com)

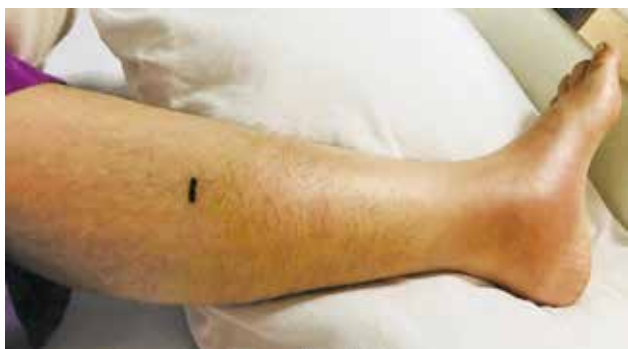

Fig 1: Swelling of the left leg

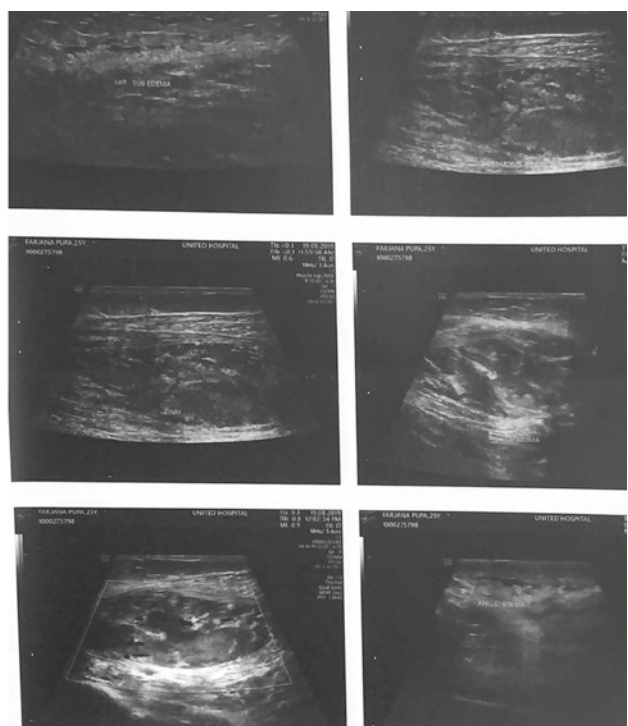


Fig 2: Ultrasonogram of the left leg showing hematoma in the medial aspect of the left leg within muscle layer and subcutaneous tissue edema noted in the medial aspect of the left leg

### Discussion:

Dengue is a mosquito-borne viral disease. It is transmitted by female mosquitoes mainly of the species *Aedes aegypti* and to a lesser extent by *Aedes albopictus*.<sup>2</sup> The serotypes are DENV-1, DENV-2, DENV-3, and DENV-4.<sup>2</sup> Primary infection with the dengue virus usually manifests as a self-limiting disease but subsequent infection by other serotypes increases the risk of developing severe dengue possibly by antibody dependent enhancement mechanism.<sup>2</sup>

Dengue virus causes asymptomatic infection to severe dengue. After the incubation period of 4 to 10 days, the illness begins abruptly and is followed by three phases—febrile, critical, and recovery.<sup>2</sup> Some people may develop severe dengue associated with severe bleeding, shock, and organ impairment. Though dengue hemorrhagic fever usually

presents with superficial bleeding like petechiae, ecchymosis, epistaxis, and gum bleeding but may present with hemoptysis, menorrhagia, hematemesis, and melaena.<sup>3</sup> In recent years there have been an increasing number of atypical presentations of dengue, especially in adults.<sup>4</sup> Spontaneous muscle hematoma is a such rare atypical presentation of DHF. A similar case from Bangladesh was reported in the British Medical Journal which manifested as compartment syndrome and occurred in the recovery phase of DHF.<sup>5</sup> Interestingly, almost all cases of spontaneous muscle hematoma are male but our case is a young lady. The cause of male preponderance is not yet known. Spontaneous muscle hematoma is seen usually in obesity, pregnancy, female gender, chronic cough, and anticoagulation therapy.<sup>6</sup> Other reported cases of intramuscular hematoma were involved the rectus sheath, psoas muscle, iliacus muscle, iliopsoas muscle, and oblique muscle of the abdomen.<sup>7,8,9,10</sup> The consequences of hematoma can be varied. They could be asymptomatic, could lead to shock, or may compress nerves leading to compression syndrome, and may be life threatening. The exact pathogenesis of bleeding in dengue fever is still unknown. Spontaneous bleeding in a patient with DHF results from the combination of thrombocytopenia, increased vascular permeability, increased fibrinolysis, and altered balance in pro-coagulation and anticoagulation factors.<sup>11</sup> Vasculopathy is caused by TNF- $\alpha$ , IL-6 & IL-8 mediated damage to the endothelial layer exposing the subendothelial von Willebrand (vWF) that leads to platelet aggregation.<sup>12</sup> In a prospective study reported by Wills et al. in 2002, 167 Vietnamese children showed minor prolongation of PT and APTT, as in our patient.<sup>13</sup> Moderate decrease in fibrinogen level was also noted.<sup>13</sup> Interactions between NS1 and the endothelial glycocalyx layer may cause a change in filtration characteristics, resulting in the leakage of plasma proteins and the release of heparan sulfate into circulation. Heparan sulfate, which can function as an anticoagulant, might contribute to coagulopathy.<sup>2</sup>

Inter-muscular and intra-muscular hematoma, though uncommon, should always be considered in any diagnosed dengue patient with acute pain. It is crucial to monitor hemoglobin, hematocrit, and platelet count daily. Most muscle hematoma in DHF can be managed conservatively as most cases resolve spontaneously. Few cases need platelet transfusion if platelets become very low. The soleus is located in the superficial posterior compartment of the leg. The action of the calf muscles, including the soleus, is plantar flexion of the foot. They are powerful muscles and are vital in walking, running, and keeping balance. Due to the thick fascia covering the muscles of the leg, they are prone to compartment syndrome. So, bleeding in the soleus muscle may cause inflammation of tissue affecting blood flow and compressing nerves. But our patient did not present with compartment syndrome and so, she was treated conservatively with limb elevation and active leg exercises, and no surgical intervention was required.

### Conclusion:

Dengue fever is increasing day by day and at the same time

there is an increasing number of newer and atypical presentations being reported especially in the recovery phase of dengue fever. So, we should always remain vigilant to prevent complications and combat new complications of dengue fever.

#### References:

1. Directorate General of Health Services, Bangladesh. Dengue Press Releases 31.12.2023. Available from: <https://old.dghs.gov.bd/index.php/bd/home/5200-daily-dengue-status-report>. (Accessed on 19 February 2023)
2. National Guideline for Clinical Management of Dengue Syndrome. 4<sup>th</sup> Edition (Revised). Available from: <https://old.dghs.gov.bd/index.php/en/home/5431-revised-guideline-for-clinical-management-of-dengue>. (Accessed on 19 February 2023)
3. Sellahewa KH. Haematological Disturbances in Dengue Haemorrhagic Fever - its Pathogenesis and Management Perspectives. *Journal of Hematology and Oncology Research* 2015; 1(3): 15-24.
4. World Health Organization. Comprehensive Guidelines for Prevention and Control of Dengue and Dengue Haemorrhagic Fever. Revised and expanded edition. New Delhi: World Health Organization, Regional Office for South-East Asia, 2011. Available from: <https://apps.who.int/iris/handle/10665/204894?show=full>. (Accessed on 19 February 2023)
5. Anam AM, Rabbani R, Shumy F. Spontaneous calf haematoma in severe dengue. *BMJ Case Rep* 2018. doi:10.1136/bcr-2017-222932
6. Eckhoff K, Wedel T, Both M, Bas K, Maass N, Alkatout I. Spontaneous rectus sheath hematoma in pregnancy and a systematic anatomical workup of rectus sheath hematoma: a case report. *Journal of Medical Case Reports* 2016; 10:292.
7. Koshy JM, John M, Rathore S, George UB. Spontaneous muscle hematomas in a patient with Dengue hemorrhagic fever. *Journal of Case Reports* 2014; 1(3): 201-202.
8. Haque HF, Ahmed AKMS, Bashar FB, Anjum R. Spontaneous muscle hematoma complicating dengue hemorrhagic fever: a case report. *BIRDEM Med J* 2020; 10(1): 76-77.
9. Pallivalappil B, Naga SR, Dipu KP, Manappallil RG. Spontaneous Muscle Hematoma in Dengue Hemorrhagic Fever: A Report of Four Cases. *Journal of Case Reports* 2018;8(2):115-119.
10. Nelwan EJ, Angelina F, Adiwinata R, Matondang S, Andrioc P. Spontaneous rectus sheath hematomas in dengue hemorrhagic fever: A case report. *IDCases* 2017; 10: 15-17. Available from: <http://dx.doi.org/10.1016/j.idcr.2017.08.004>
11. Matthias AT, Apsara S, Epa A. A case report of dengue haemorrhagic fever complicated with psoas haematoma requiring blood transfusion. *BMC Infect Dis* 2019; 19: 385.
12. Suseno A, Nasronudin N. Pathogenesis of haemorrhage due to dengue virus. *Indonesian Journal of Tropical and Infectious Disease* 2015; 5(4): 107-111.
13. Wills BA, Oragui EE, Stephens AC, Daramola OA, Dung NM, Loan HT, et al. Coagulation Abnormalities in Dengue Hemorrhagic Fever: Serial Investigations in 167 Vietnamese Children with Dengue Shock Syndrome. *Clin Infect Dis* 2002; 35(3): 277-85.