

Clinical Image**A case of reversible cytotoxic lesion of corpus callosum (CLOCCs) secondary to septic encephalopathy caused by suspected enteric fever**Tamanna Yasmin Shena¹, Umme Kulsum Chy², Amina Sultana³, Mohammad Omar Faruq⁴DOI: <https://doi.org/10.3329/bccj.v11i2.69149>**Case:**

A 16 years old Bangladeshi boy with no known comorbidities was admitted on 13th June 2023 through emergency under the Department of Critical Care Medicine with the complaints of fever which was initially low grade, intermittent and then became high grade with highest recorded temperature 106°F for 13 days, H/O loose motion and vomiting for several episodes, irrelevant talk and severe restlessness for 3 days. On Examination patient was drowsy, disoriented, severely restless, GCS E₄M₃V₃ (12/15), Pupil bilaterally 2.5 mm reacting to light, bilateral plantar flexor with no focal neurological deficit and there was no signs of neck rigidity. He was haemodynamically stable with temp 105°F and maintaining SPO₂ in room air. His blood investigations revealed severe sepsis (procalcitonin 75) with Pancytopenia, AKI (S. Creatinine 2.25 mg/dl; B. Urea 64 mg/dl) with hypokalaemia. His widal test was strongly positive (TO 1:320; TH 1:320) with USG of whole abdomen revealing mild hepatosplenomegaly suggestive of enteric fever. His CT brain and CSF study revealed normal and blood C/S revealed no growth. On next day of admission, MRI brain was done which showed finding that corresponds to cytotoxic lesion/ acute infarct in splenium of corpus callosum (Figure 1). Patient was treated accordingly with broad spectrum injectable antibiotics, Blood transfusion, IV fluids, electrolyte correction, antipyretic and NG feeding. From the 3rd day of admission he showed significant signs of improvement. He became afebrile, conscious and oriented with significant improvement of laboratory parameters. As the following day patient attendant took discharge against medical advice, they were suggested to do a follow up MRI and continue injectable antibiotic for total 14 days.

1. Specialist, General ICU, United Hospital Limited, Dhaka
2. Junior Consultant, General ICU, United Hospital Limited, Dhaka, Bangladesh.
3. Consultant, General ICU and ED, United Hospital Limited, Dhaka, Bangladesh.
4. Chief Consultant, General ICU and Emergency, United Hospital Limited, Dhaka, Bangladesh.

Corresponding Author:

Dr. Tamanna Yasmin Shena
 MBBS, MRCP (UK), MD (CCM)
 Specialist, General ICU
 United Hospital Limited, Dhaka 1212, Bangladesh
 e-mail: shenayasmin@gmail.com

Discussion :

The corpus callosum forms the bridge between the cerebral hemispheres, containing crossing axonal fibers from both hemispheres¹. Cytotoxic lesions of the corpus callosum (CLOCCs) are secondary lesions associated with various entities². CLOCCs is an imaging finding that usually resolves within the first month of the neurological symptoms³. Cytotoxic lesions of the corpus callosum are caused by a long list of different factors that include antiepileptic drugs, withdrawal of antiseizure drugs, epilepsy, migraine with aura, trauma, viruses (Epstein-Barr virus, rotavirus, influenza, parainfluenza, measles, mumps, cytomegalovirus, varicella-zoster, human herpesvirus-6, human herpesvirus-7, adenovirus, human parvovirus B19, rubella, human immunodeficiency virus, and enterovirus), bacteria (Salmonella, Staphylococcus aureus, Legionella pneumophila, Escherichia coli, Klebsiella pneumoniae, Mycoplasma pneumoniae, Streptococcus pneumoniae, Campylobacter jejuni, and Enterococcus faecalis), malaria parasite, dengue fever, Kawasaki disease, renal failure, hemolytic uremic syndrome, autoimmune diseases, radiation therapy, metabolic diseases, mumps vaccine, malignancy, subarachnoid hemorrhage, high-altitude cerebral edema, and several pharmacological and toxic substances^{2,3,4}. In all of these conditions, cell-cytokine interactions lead to markedly increased levels of cytokines and extracellular glutamate. Ultimately, this cascade can lead to dysfunction of the callosal neurons and microglia. Cytotoxic edema develops as water becomes trapped in these cells. On diffusion-weighted magnetic resonance (MR) images, CLOCCs manifest as areas of low diffusion. CLOCCs lack enhancement on contrast material-enhanced images, tend to be midline, and are relatively symmetric² which is in our case. The corpus callosum and, particularly, the splenium, is highly involved during cytokinopathies, due to the abundant quantity of cytokine and glutamate receptors, more than in any other site of the brain².

The involvement of the corpus callosum typically shows one of three patterns: (a) a small round or oval lesion located in the center of the splenium, (b) a lesion centered in the splenium but extending through the callosal fibers laterally into the adjacent white matter, or (c) a lesion centered posteriorly but extending into the anterior corpus callosum². Transient lesions of the corpus callosum was first reported by Kim et al. in 1999 who noted the disappearance of focal lesions in the splenium of corpus callosum of two patients after withdrawing

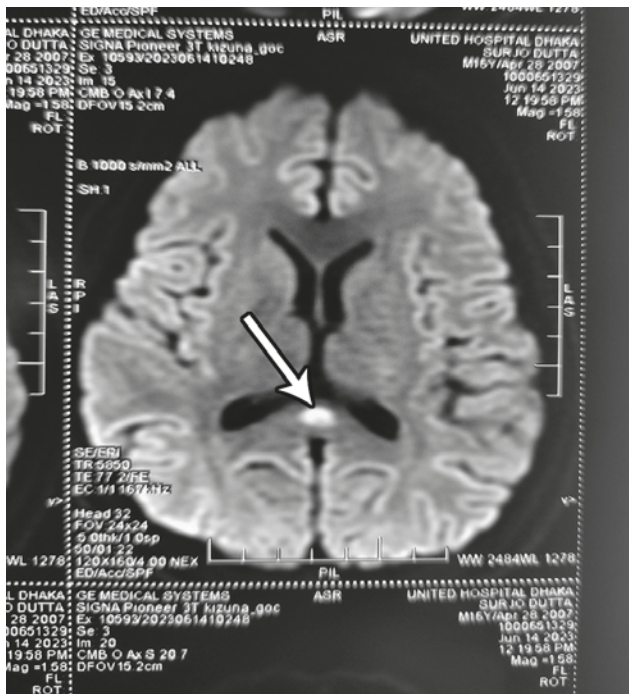


Figure 1: MRI brain of patient showing cytotoxic lesion of corpus callosum (arrow marking)

antiepileptic drugs⁵. Over the years, this entity has been variously described as mild encephalitis/encephalopathy with a reversible splenial lesion (MERS)⁶ or reversible splenial lesion syndrome (RESLES)⁷. However the term cytotoxic lesions of the corpus callosum (CLOCC) is now considered most appropriate². Infarctions can be one of the causes of such lesions, but infarctions restricted to the CC are rare because of its rich blood supply from the different arteries bilaterally⁸. CLOCCs are frequently but not invariably reversible. Although CLOCCs are nonspecific with regard to the underlying cause, additional imaging findings and the clinical findings can aid in making a specific diagnosis. Radiologists should be familiar with the imaging appearance of CLOCCs to avoid a misdiagnosis of ischemia. When CLOCCs are found, the underlying cause of the lesion should be sought and addressed².

References :

1. Blaauw J, Meiners LC. The splenium of the corpus callosum: embryology, anatomy, function and imaging with pathophysiological hypothesis. *Neuroradiology* 2020;62:563–85.
2. Starkey J, Kobayashi N, Numaguchi Y, et al. Cytotoxic lesions of the corpus callosum that show restricted diffusion: mechanisms, causes, and manifestations. *Radiographics* 2017; 37(2): 562–576. [PubMed] [Google Scholar]
3. Tetsuka S. Reversible lesion in the splenium of the corpus callosum. *Brain Behav* 2019;9:e01440.
4. Sahu A, Sankhe S, Mittal K, et al. A pictorial review on reversible splenial lesions. *Indian J Radiol Imaging* 2021; 31(1): 3–9. [PMC free article] [PubMed] [Google Scholar]
5. Kim SS, Chang KH, Kim ST et al (1999) Focal lesion in the splenium of the corpus callosum in epileptic patients: antiepileptic drug toxicity? *Am J Neuroradiol* 20(1):125–129.
6. Tada H, Takanashi J, Barkovich AJ et al (2004) Clinically mild encephalitis/encephalopathy with a reversible splenial lesion. *Neurology* 63:1854–1858.
7. Garcia-Monco JC, Cortina IE, Ferreira E et al (2011) Reversible splenial lesion syndrome (RESLES): what's in a name? *J Neuroimaging* 21:e1–e14.
8. Li S, Sun X, Bai Y et al. Infarction of the corpus callosum: a retrospective clinical investigation. *PLoS One* 2015;10:e0120409.