

Case Report

Pancytopenia, a new manifestation in Post-Covid Syndrome

Sharmin Rahman^{1*}, Syeda Fahmida Hossain², Karishma Shamarukh³

DOI: <https://doi.org/10.3329/bccj.v9i2.56162>

Abstract:

Pancytopenia is a condition where all three types of blood cell counts simultaneously become low. There are multiple factors for which pancytopenia might occur; however pancytopenia because of Covid-19 have been reported rarely. Here, we discussed a case of pancytopenia, which presented to us as a consequence of Covid-19 infection.

Key words: Pancytopenia, Covid-19, Bone marrow study, Post-Covid syndrome, G-CSF.

Introduction:

The concurrent presence of anaemia, leucopenia and thrombocytopenia is called pancytopenia. It occurs when Hemoglobin (Hb) is less than 13.5g/dl in males or 11.5g/dl in females; the leucocytes count is less than $4 \times 10^3/l$ and the platelets count is less than $150 \times 10^3/l$ ¹

In the primary stage, symptoms of pancytopenia might not be pronounced if the body functions normally, however, in times of stress (i.e., bleeding or infection), pancytopenia might be marked with various manifestations. The underlying mechanisms leading to pancytopenia are, decrease in hematopoietic cell production, marrow replacement by abnormal cells, suppression of marrow growth and differentiation, ineffective hematopoiesis with cell death, defective cell formation which are removed from the microcirculation, antibody mediated sequestration or destruction of cells and trapping of cells in a hypertrophied and over active reticuloendothelial system².

The usual manifestation of Covid-19 infection is respiratory symptoms, such as respiratory distress. However, we should also bear in mind the extra-pulmonary manifestations, including cardiac, gastrointestinal, hepatic, renal, neurological, olfactory, gustatory, ocular, cutaneous and haematological symptoms³.

Pancytopenia is a very common problem attended to in our day to day practice. When evaluating patients with unexplained anemia, prolonged fever and tendency to bleed, pancytopenia should be considered as a differential. Detailed primary hematological investigations along with bone marrow aspiration in cytopenic patients are helpful for understanding the disease process; to diagnose, or to rule out the causes of pancytopenia; and in planning further

investigations and management of cytopenic patients. Severe pancytopenia has significant relation to the clinical outcome and can be used as a prognostic indicator⁴.

Various hematopoietic and non-hematopoietic conditions manifest with features of pancytopenia⁵.

Case Report:

A 62 years old gentleman with known DM and IHD (S/P PTCA), and a recent history of hospitalization Covid-19 pneumonia, and recovered only 1 week back, presented in our A & E department, with the complaints of, per rectal fresh bleeding for 4 times. Initially the patient was admitted in the department of general surgery, however, finding no local pathology indicative of cause of fresh per rectal bleeding, he was then transferred to the Internal Medicine department.

On admission, he was conscious and oriented, anemic, afebrile, BP: 120/80 mmHg, Pulse: 96b/min (regular), SpO₂: 96% with 2 litre of Oxygen, RBS: 12.3mmol/L, P/R examination revealed fresh blood and no evidence of anal fissure and hemorrhoids. Other general and systemic examinations revealed no abnormalities.

Laboratory findings revealed, Hb: 7.1gm/dl (13-18gm/dl), RBC: $3.2 \times 10^6 /\mu l$ ($4.5-5.5 \times 10^6 /\mu l$), WBC: $2.6 \times 10^3 /\mu l$ ($4-11 \times 10^3 /\mu l$), Platelet: $40 \times 10^3 /\mu l$ ($150-450 \times 10^3 /\mu l$), Peripheral blood film revealed Pancytopenia, Ferritin: 72 $\mu g/L$ (20-300 $\mu g/L$), PT 13.0 S (9.8-13.S), D-Dimer and CRP were within normal range, Chest X-ray revealed evidence of COVID infection. Bone marrow study was suggestive of 'toxic hold up' with no evidence of lymphoma, fibrosis or myelodysplasia. His RT-PCR for Covid-19 was negative. One week back, during the previous discharge his blood picture had been completely normal.

He was transfused with 1 unit of fresh whole blood, Tazobactam and Moxiquin was given to prevent any kind of secondary bacterial infection, a stat dose of Granulocyte colony stimulating factor (G-CSF) was given subcutaneously. Oral Prednisolone 10mg was started which was tapered to 2mg later on and other supportive measures were given to the patient. He was already getting Nintedanib for his pulmonary fibrosis. A week later his rectal bleeding stopped, Hb rose to 13gm/dl, RBC $5.0 \times 10^6 /\mu l$, WBC $5 \times 10^3 /\mu l$ and Platelet $175 \times 10^3 /\mu l$. His PBF also returned to normal after a week.

1. Specialist, Internal Medicine, United Hospital Ltd.
2. Consultant, Internal Medicine, United Hospital Ltd.
3. Intensivist, Covid-ICU, United Hospital Ltd.

*Corresponding Author:

Dr. Sharmin Rahman

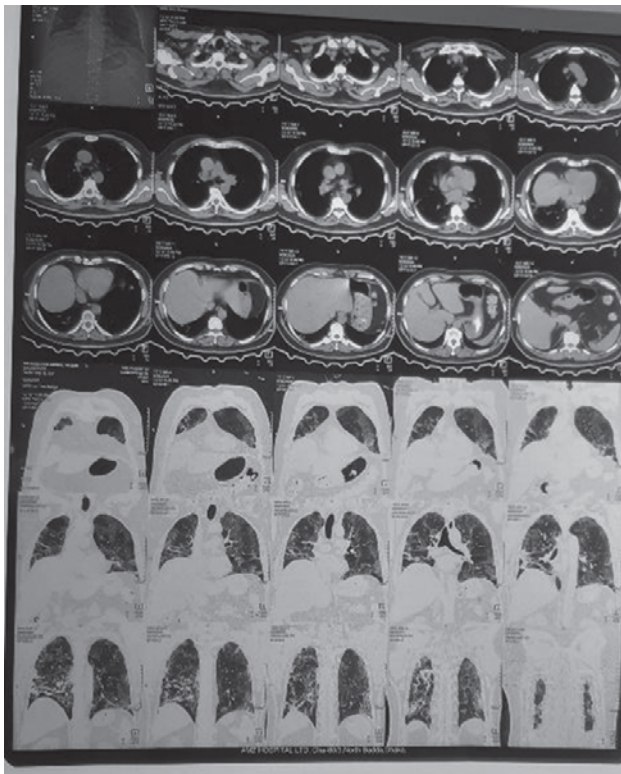
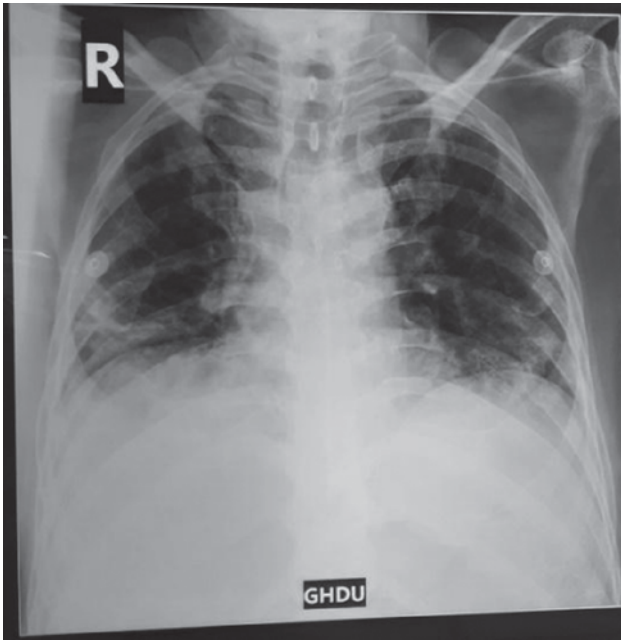
Specialist

Internal Medicine

United Hospital Limited, Dhaka 1212, Bangladesh.

Email: nsharminrahman@yahoo.com

Cell: +88 01787002829



Discussion:

The commonest clinical manifestations of Pancytopenia are usually Fever (86.7%), fatigue (76%), dizziness (64%), weight loss (45.3%), anorexia (37.3%), night sweats (28%), pallor (100%), bleeding (38.7%), splenomegaly (48%), hepatomegaly (21.3%), and lymphadenopathy (14.7%)⁶

Our patient presented with per rectal bleeding following

Covid pneumonia. The various causes of pancytopenia are usually found out by bone marrow study. In our patient the bone marrow study showed no such causes, the toxic hold up might have been an effect of post-Covid infection, as we ruled out every other possible cause of pancytopenia.

There have been very few case reports on Pancytopenia during or following Covid-19 infection. In one of the case studies, a 53 year old gentleman with a history of mantle cell lymphoma in complete remission presented with acute respiratory distress, pancytopenia and cytokine release syndrome⁷. Later on he was found to be Covid-19 positive. After proper clinical evaluation he was given high flow oxygen and non-invasive ventilation. His condition gradually improved over 2 weeks, however, pancytopenia persisted. In another case report, a 49 year old gentleman who was a known case of follicular cell lymphoma grade 3A, stage 4A, admitted with fever and symptoms of an upper respiratory tract infection⁸. Throat swab was positive for COVID-19. He was discharged and 10 days later he again presented with flu-like symptoms, but this time his blood workup showed features of pancytopenia. Bone marrow biopsy to investigate the cause of pancytopenia found nonspecific reactive changes, with no sign of lymphoma, fibrosis or myelodysplasia. His blood picture reverted to normal state, once his infection was controlled.

There is an association of immune thrombocytopenia with covid-19, however the mechanism is yet unknown⁹. Lymphopenia was also reported in Covid-19 infection¹⁰.

Various viral infections are to be found as a causal factor of pancytopenia¹¹. For our case study, we can hypothesize Covid-19 virus was causing the toxic hold up which resulted in pancytopenia. On the other hand, Covid-19 causes cytokine storm, this cytokine storm produces hemophagocytosis which results in consumption of hematopoietic elements (erythrocytes, leukocytes, or platelets), which also could have been the cause of pancytopenia in Covid-19 infection^{12,13}.

Pancytopenia is not a disease itself, rather a description of laboratory findings in which all three lines of blood cells have been reduced. Here, pancytopenia is found as a manifestation of post-Covid syndrome. Covid-19 can virtually involve any organs in the body. Post-Covid Pulmonary fibrosis has been reported in numerous cases almost all over the world^{14,15}. We need to consider post-Covid pancytopenia as one of syndromes associated with Covid-19 infection.

Bone marrow biopsy is an important tool to diagnose pancytopenia. Patients with pancytopenia need careful follow-up and treatment should be directed against catching up with any kind of secondary bacterial infection with other supportive measures.

Marrow support should be given to treat pancytopenia. Blood transfusion causes rise in Hb level, in some cases platelet transfusion might also be needed. G-CSF is given for neutropenia. Measures should be taken to prohibit any kind of superadded infection.

Conclusion:

Pancytopenia as an effect of Covid-19 infection is one of the new impacts of this deadly virus. Clinicians need to be aware of this complication of Covid-19 and further case studies are necessary to identify the exact mechanism of pancytopenia in post-Covid syndromes or Covid-19 infection.

References:

1. Khunger JM, Arulselvi S, Sharma U, Ranga S, Talib V. Pancytopenia--a clinico haematological study of 200 cases. *Indian journal of pathology & microbiology*. 2002;45(3):375-9.
2. Makheja KD, Maheshwari BK, Arain S, Kumar S, Kumari S. The common causes leading to pancytopenia in patients presenting to tertiary care hospital. *Pakistan journal of medical sciences*. 2013;29(5):1108.
3. Lai C-C, Ko W-C, Lee P-I, Jean S-S, Hsueh P-R. Extra-respiratory manifestations of COVID-19. *International journal of antimicrobial agents*. 2020;56(2):106024.
4. Rao KS. Pancytopenia: a clinico hematological study. *Journal of laboratory physicians*. 2011;3(01):015-20.
5. Jha A, Sayami G, Adhikari R, Panta A, Jha R. Bone marrow examination in cases of pancytopenia. *J Nepal Med Assoc*. 2008;47(169):12-7.
6. Imbert M, Scoazec J, Mary J, Jouzult H, Rochant H, Sultan C. Adult patients presenting with pancytopenia: a reappraisal of underlying pathology and diagnostic procedures in 213 cases. *Hematologic pathology*. 1989;3(4):159-67.
7. Issa N, Lacassin F, Camou F. First case of persistent pancytopenia associated with SARS-CoV-2 bone marrow infiltration in an immunocompromised patient. *Annals of Oncology*. 2020;31(10):1418-9.
8. Hersby D, Do T, Gang A, Nielsen T. COVID-19-associated pancytopenia can be self-limiting and does not necessarily warrant bone marrow biopsy for the purposes of SARS-CoV-2 diagnostics. *Annals of Oncology*. 2021;32(1):121-3.
9. Zulfiqar A-A, Lorenzo-Villalba N, Hassler P, Andrés E. Immune thrombocytopenic purpura in a patient with Covid-19. *New England Journal of Medicine*. 2020;382(18):e43.
10. Tavakolpour S, Rakhshandehroo T, Wei EX, Rashidian M. Lymphopenia during the COVID-19 infection: What it shows and what can be learned. *Immunology letters*. 2020;225:31.
11. Kelm DJ, Torres KM, Sohail MR, editors. 46-year-old man with fevers, chills, and pancytopenia. *Mayo Clinic Proceedings*; 2012 August; 87(8): 799-802.
12. Soy M, Keser G, Atagündüz P, Tabak F, Atagündüz I, Kayhan S. Cytokine storm in COVID-19: pathogenesis and overview of anti-inflammatory agents used in treatment. *Clinical rheumatology*. 2020;39:2085-94.
13. Canna SW, Behrens EM. Making sense of the cytokine storm: a conceptual framework for understanding, diagnosing, and treating hemophagocytic syndromes. *Pediatric Clinics*. 2012;59(2):329-44.
14. Tale S, Ghosh S, Meitei SP, Kolli M, Garbhapu AK, Pudi S. Post-COVID-19 pneumonia pulmonary fibrosis. *QJM: An International Journal of Medicine*. 2020;113(11):837-8.
15. Ojo AS, Balogun SA, Williams OT, Ojo OS. Pulmonary fibrosis in COVID-19 survivors: predictive factors and risk reduction strategies. *Pulmonary medicine*. 2020; doi: 10.1155/2020/6175964