

## Clinical Image

# Lateral Medullary Syndrome

Debasish Kumar Saha<sup>1</sup>, Madhurima Saha<sup>2</sup>, Suraiya Nazneen<sup>3</sup>

A 45-year old diabetic, hypertensive male was admitted in Intensive Care Unit (ICU) of Bangladesh Institute of Research and Rehabilitation in Diabetes, Endocrine and Metabolic Disorders (BIRDEM) with fever and respiratory distress for 2 days. He had H/O vertigo, vomiting followed by fall, altered level of consciousness and slurred speech 4 days back. He had dribbling of secretion through nose and mouth, but no H/O weakness of any side or convulsion. On examination, he was found conscious, hemodynamically stable, febrile, tachypnoeic with bilateral crepitations and transmitted sound throughout lung fields. On neurological examination, he had motor dysphasia, left sided partial ptosis with nystagmus. Immediately endotracheal intubation was done for airway protection. Antibiotics and other supportive measures started. CT scan of head (done before ICU admission) was unremarkable. So, we planned for MRI brain which revealed infarct involving left medulla oblongata. Patient's consciousness level improved gradually and then through neurological examination revealed diminished pain and temperature sensation in the left side of face and right side of body.

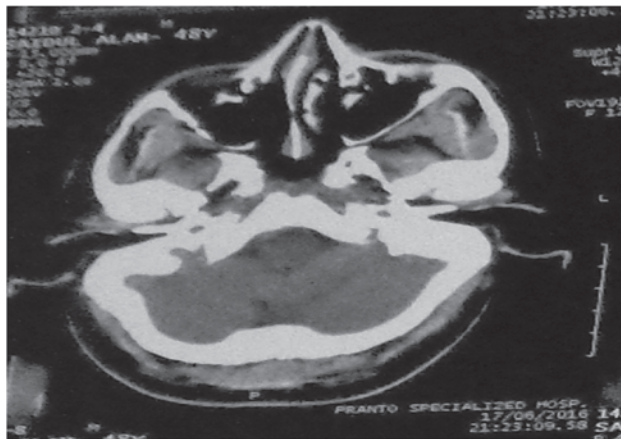


Figure 1: CT head showed unremarkable medulla

Along with the clinical findings with compatible MRI brain report, we diagnosed the patient as Lateral Medullary Syndrome and treated accordingly. His condition was improved and later shifted under Neurology department for further care.

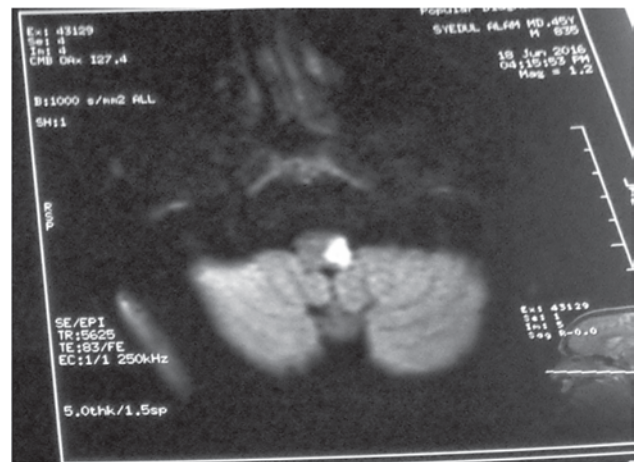


Figure 2: MRI brain showed infarct involving left lateral medulla

### Discussion:

Lateral medullary syndrome (Wallenberg syndrome) is an acute ischemic infarct due to occlusion of the vessels supplying the lateral medulla oblongata. Most commonly occlusion is intracranial portion of the vertebral artery or posterior inferior cerebellar artery (PICA) and/or its branches.

The lateral medullary syndrome was described in 1808 by Gaspard Vieussux.<sup>1</sup> First description by Wallenberg were in 1895 (clinical) and 1901 (autopsy findings).

Affected person have difficulty in swallowing (dysphagia) resulting from involvement of nucleus ambiguus, as well as slurred speech (dysarthria) and disordered vocal quality (dysphonia). Damage to the spinal trigeminal nucleus causes absence of pain on the ipsilateral side of the face and absent corneal reflex. The lateral spinothalamic tract is damaged, resulting in loss of pain and temperature sensation on the opposite side of the body. The damage to the cerebellum or inferior cerebellar peduncle can cause ataxia. Damage to the hypothalamospinal fibers disrupts sympathetic nervous system relay and gives symptoms analogous to Horner's Syndrome.

Nystagmus and vertigo may caused from involvement of the region of Deiters' nucleus and other vestibular nuclei. Palatal myoclonus may be observed due to disruption of the central tegmental tract. Although in Wallenberg syndrome, the lesion due to lateral medullary infarction is unilateral, its effect on oropharyngeal swallowing is bilateral.<sup>2</sup>

1. Dr. Debasish Kumar Saha, FCPS (Medicine), Registrar, Dept of Critical Care Medicine, BIRDEM.
2. Dr. Madhurima Saha, FCPS (Medicine), Registrar, Dept of Critical Care Medicine, BIRDEM.
3. Dr. Suraiya Nazneen, FCPS (Medicine), Registrar, Dept of Critical Care Medicine, BIRDEM.

### Corresponding Author:

Dr. Debasish Kumar Saha  
FCPS (Medicine)  
Registrar  
Dept. of Critical Care Medicine  
BIRDEM General Hospital  
Email: debasish81dmc@yahoo.com

Brain imaging (CT/MRI) can confirm the diagnosis.<sup>3-5</sup> Treatment for lateral medullary syndrome involves focusing on relief of symptoms and active rehabilitations. The outlook depends upon the size and location of the area of the brain stem damaged by the stroke.

**References:**

1. Kim H, Chung CS, Lee KH, Robbins J. Aspiration subsequent to a pure medullary infarction: lesion site, clinical variables and outcome. Arch neurol 2005; 57: 478-83.
2. Aydogdu I, Ertckin C, Tarlaci S, Turman B, Kiylioglu N, Secil Y. Dysphagia in lateral medullary infarction(lateral mdullary syndrome) : an acute dysconnection syndrome in premotor neurons relate to swallowing activity. Stroke 2001; 32: 2081-7.
3. Sacco RL, Freddo L, Bello JA, Odel JG, Onesti ST, Mohr JP. Wallenberg's lateral medullary syndrome : clinical- magnetic resonance imaging correlations Arch Neurol 1993; 50: 609-14.
4. Kim JS. Pure lateral medullary infarction: clinical-radiological correlation of 130 acute, consecutive patients. Brain 2003; 126(8):1864-72.
5. Kim JS, Lee JH, Choi CG. Patterns of lateral medullary infarction: vascular lesion-magnetic resonance imaging correlation of 34 cases. Stroke 1998; 29(3): 645-52.