

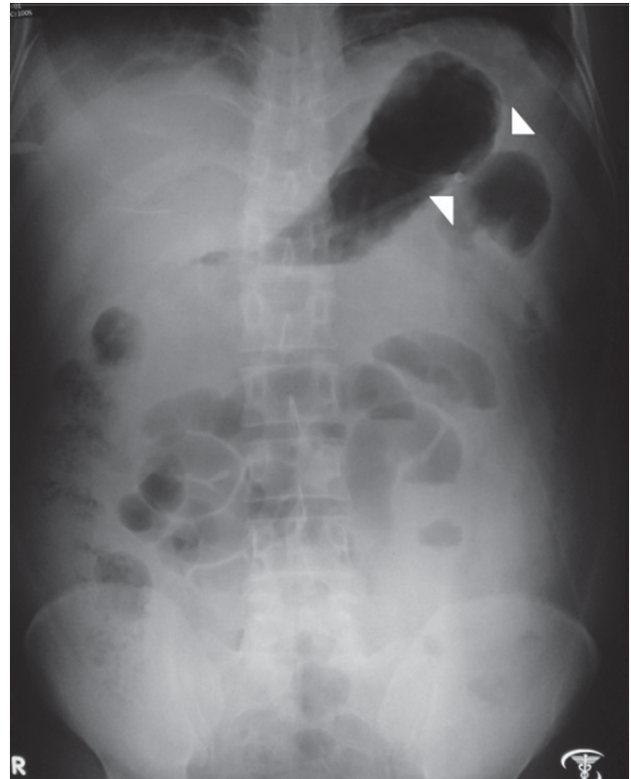
## Clinical Image

# Colon Cutoff Sign

Ahmad Mursel Anam<sup>1</sup>, Farzana Shumy<sup>2</sup>, Shahzadi Sayeeda Tun Nessa<sup>3</sup>, Raihan Rabbani<sup>4</sup>

A 56-year-old gentleman, a diabetic and alcoholic, presented with sudden severe epigastric pain and recurrent episodes of vomiting. The pain was sharp, stabbing in nature, radiated to back, and mildly improved on leaning forward. On examination, the patient was in agony with pain, had tachycardia and hypotension, and abdomen was mildly distended, tender and bowel sound was absent. An urgent plain x-ray of abdomen was done, revealed distended large bowel, with “colon cutoff sign” [Figure]. Acute pancreatitis was suspected from clinical features and abdominal radiographic findings, which was confirmed with raised pancreatic enzymes and CT scan of abdomen. He was treated conservatively, with early enteral feeding and analgesics. He was discharged in improved clinical condition, on 10<sup>th</sup> day following admission.

Abrupt termination of proximal colonic gas shadow at the level of the radiographic splenic flexure, usually with decompression of the distal colon is known as the colon cutoff sign. The findings can be seen on conventional abdominal radiographs, computed tomographic (CT) and intraluminal contrast material enema studies. Inflammatory exudate in acute pancreatitis extends into the phrenicocolic ligament by directly spreading through the lateral attachment of the transverse mesocolon and results in functional spasm and/or mechanical narrowing of the splenic flexure. This “cutoff”, is further accentuated by distention of the intraperitoneal transverse colon from the focal adynamic ileus, also resulting from the underlying inflammatory process.<sup>1</sup>



**Figure :** Plain x-ray abdomen showing distended colon, with abrupt termination of gas shadow (white arrowheads) – the “colon cutoff sign”

1. Dr. Ahmad Mursel Anam, MBBS, Chief Resident, ICU, Square Hospitals Ltd., Dhaka 1205, Bangladesh
2. Dr. Farzana Shumy, FCPS (Medicine), Medical Officer, Department of Internal Medicine, Bangabandhu Sheikh Mujib Medical University, Shahbagh, Dhaka 1000, Bangladesh
3. Dr. Shahzadi Sayeeda Tun Nessa, MBBS, Clinical Staff, ICU, Square Hospitals Ltd., Dhaka 1205, Bangladesh
4. Dr. Raihan Rabbani, FCPS (Medicine), MD (USA), Consultant, ICU, Square Hospitals Ltd., Dhaka 1205, Bangladesh

### Corresponding Author :

Dr. Ahmad Mursel Anam  
MBBS  
Chief Resident, ICU, Square Hospitals Ltd.  
18/F, BU Qazi Nuruzzaman Sarak  
Dhaka 1205, Bangladesh  
Email: murselanam@gmail.com

Sensitivity of the colon cutoff sign in acute pancreatitis depends upon several factors, and has been found up to 52% in different studies.<sup>2</sup> Neoplastic and other inflammatory conditions at the splenic flexor can produce radiographic “colon cutoff” appearance. Other disorders, like splenic artery hemorrhage, abdominal aortic aneurysm rupture, and postpancreatitis stricture can also result in focal narrowing at the splenic flexure of colon. Therefore, it is a nonspecific finding, although this feature is most commonly associated with acute pancreatitis.<sup>1</sup>

As plain x-ray abdomen is most often, the first imaging modality advised for patients with abdominal complaints, recognition of the radiographic features associated with acute pancreatitis, including the colon cutoff sign is important for early diagnosis and management.

### References :

1. Pickhardt PJ. The Colon Cutoff Sign. *Radiology* 2000;215(2):387–389.
2. Brascho DJ, Reynolds TN, Tanca P. The Radiographic “Colon Cut-off Sign” in Acute Pancreatitis. *Radiology* 1962;79:763–769.